

Cytoreductive Surgery and Hyperthermic Intraperitoneal Chemotherapy in the Management of Peritoneal Surface Malignancies of Colonic Origin: A Consensus Statement

J. Esquivel,¹ R. Sticca,² P. Sugarbaker,³ E. Levine,⁴ T. D. Yan,³ R. Alexander,⁵ D. Baratti,⁶ D. Bartlett,⁷ R. Barone,⁸ P. Barrios,⁹ S. Bieligk,¹⁰ P. Bretcha-Boix,¹¹ C. K. Chang,¹² F. Chu,¹³ Q. Chu,¹⁴ S. Daniel,¹³ E. deBree,¹⁵ M. Deraco,⁶ L. Dominguez-Parra,¹⁶ D. Elias,¹⁷ R. Flynn,¹⁰ J. Foster,¹⁸ A. Garofalo,¹⁹ F. N. Gilly,²⁰ O. Glehen,²⁰ A. Gomez-Portilla,²¹ L. Gonzalez-Bayon,²² S. Gonzalez-Moreno,²³ M. Goodman,²⁴ V. Gushchin,²⁵ N. Hanna,⁵ J. Hartmann,²⁶ L. Harrison,²⁷ R. Hofer,²⁸ J. Kane,²⁹ D. Kecmanovic,³⁰ S. Kelley,³¹ J. Kuhn,³² J. LaMont,³² J. Lange,³³ B. Li,¹⁴ B. Loggie,¹⁸ H. Mahteme,³⁴ G. Mann,³⁵ R. Martin,³⁶ R. A. Misih,³⁷ B. Moran,³⁸ D. Morris,¹³ L. Onate-Ocana,³⁹ N. Petrelli,³⁷ G. Philippe,⁴⁰ J. Pingpank,⁴¹ A. Pitroff,¹ P. Piso,⁴² M. Quinones,⁴³ L. Riley,⁴⁴ L. Rutstein,⁴⁵ S. Saha,⁴⁶ S. Alrawi,²⁹ A. Sardi,²⁵ S. Schneebaum,⁴⁷ P. Shen,⁴ D. Shibata,³¹ J. Spellman,⁴⁸ A. Stojadinovic,⁴⁹ J. Stewart,⁴ J. Torres-Melero,⁵⁰ T. Tuttle,⁵¹ V. Verwaal,⁵² J. Villar,⁵³ N. Wilkinson,⁵⁴ R. Younan,⁶ H. Zeh,⁷ F. Zoetmulder,⁵² and G. Sebbag⁵⁵

¹St. Agnes Hospital, Baltimore, MD, USA

²Altru Hospital, University of North Dakota, Grand Forks, ND, USA

³Washington Hospital Center, Washington, DC, USA

⁴Wake Forest University, Winston-Salem, NC, USA

⁵University of Maryland, Baltimore, MD, USA

⁶National Cancer Institute of Milan, Milan, Italy

⁷University of Pittsburgh Medical Center, Pittsburgh, PA, USA

⁸Sharp Healthcare Hospital, San Diego, CA, USA

⁹Hospital de San Pablo, Barcelona, Spain

¹⁰Baltimore-Washington Medical Center, Glenn Burnie, MD, USA

¹¹Hospital San Jaime, Torrevieja, Spain

¹²Walnut Creek Kaiser Permanente, Walnut Creek, CA, USA

¹³St. George Hospital, Sydney, Australia

¹⁴Louisiana State University, Shreveport, LA, USA

¹⁵Medical School of Crete University Hospital, Herakleion, Greece

¹⁶Instituto Nacional de Cancerlogia, Distrito Federal, Mexico

¹⁷Institut Gustave Roussy, Villejuif, France

¹⁸Creighton University Medical School, Omaha, NE, USA

¹⁹Ospedale S. Camillo-Forlanini, Rome, Italy

²⁰University of Lyon, Lyon, France

²¹Policlinica San Jose, Vitoria, Spain

²²Hospital General Universitario Gregorio Maranon, Madrid, Spain

²³MD Anderson España, Madrid, Spain

²⁴Dorothy E. Schneider Cancer Center, San Mateo, CA, USA

²⁵Mercy Medical Center, Baltimore, MD, USA

²⁶Charite Hospital Campus Mitte, Berlin, Germany

Received June 2, 2006; accepted June 2, 2006

Address correspondence and reprint requests to: J. Esquivel;
E-mail: jesusesquivel@yahoo.com

Published by Springer Science+Business Media, Inc. © 2006 The Society of
Surgical Oncology, Inc.

- ²⁷University of Medicine and Dentistry of New Jersey, Newark, NJ, USA
²⁸Surgical Oncology Associates, Newport News, VA, USA
²⁹Roswell Park Cancer Center, Buffalo, NY, USA
³⁰First Surgical University Hospital, Belgrade, Serbia
³¹H. Lee Moffitt Cancer Center, Tampa, FL, USA
³²Baylor University Medical Center, Dallas, TX, USA
³³Johns Hopkins Hospital, Baltimore, MD, USA
³⁴Akademiska University Hospital, Uppsala, Sweden
³⁵University of Washington, Seattle, WA, USA
³⁶University of Louisville, Louisville, KY, USA
³⁷Helen F Graham Cancer Center, Newark, DE, USA
³⁸North Hampshire Hospital, Basingstoke, United Kingdom
³⁹Hospital Medica Sur, Tlalpan, Mexico
⁴⁰Surgical Departement Kantonsspital, St. Gallen, Switzerland
⁴¹National Cancer Institute of USA, Bethesda, MD, USA
⁴²University of Regensburg, Regensburg, Germany
⁴³Dekalb Medical Center, Decatur, GA, USA
⁴⁴St. Luke's Hospital, Bethlehem, PA, USA
⁴⁵Maine Medical Center, Portland, ME, USA
⁴⁶Miami Valley Hospital, Xenia, OH, USA
⁴⁷Tel-Aviv Sourasky Medical Center, Tel-Aviv, Israel
⁴⁸Beebe Medical/ Christiana Care, Lewes, DE, USA
⁴⁹Walter Reed Army Medical Center, Washington, DC, USA
⁵⁰Hospital Torrecardenas, America, Spain
⁵¹Fairview University Medical Center, Minneapolis, MN, USA
⁵²Netherlands Cancer Institute, Amsterdam, Holland
⁵³Hospital Virgen de la Nieves, Granada, Spain
⁵⁴University of Iowa, Iowa City, IA, USA
⁵⁵Soroka University Medical Center, Beer Sheva, Israel

Surgical resection remains the hallmark therapy for primary colon cancer. It allows the patients to become clinically disease free, provides proper staging, and determines who should receive adjuvant systemic chemotherapy. Treatment options for patients with unresectable metastatic disease have improved significantly in the past few years. A review of the published data in the treatment of patients with stage IV colorectal cancer, outlining the surgical and medical therapeutic options demonstrates that medical management, with combinations of cytotoxic chemotherapy, and/or biological agents, has resulted in an unprecedented median survival > 20 months. However, these therapeutic combinations are not an optimal therapeutic strategy for all categories of stage IV disease. Systemic treatment alone is no longer appropriate for patients with limited peritoneal dissemination from a primary or recurrent colon cancer. The surgical management of peritoneal surface malignancies of colonic origin with cytoreductive surgery and hyperthermic intraperitoneal chemotherapy (HIPEC) has been clearly defined and continues to improve. Better surgical techniques that include peritonectomy procedures, standardized

methods to deliver intraoperative hyperthermic intraperitoneal chemotherapy and better patient selection criteria, have resulted in a significant improvement in survival and in morbidity and mortality of the surgical management of this particular group of stage IV colon cancer patients.

MATERIALS AND METHODS

Upon review of the literature, we have identified a subset of patients with metastatic disease confined to the abdomen and with no evidence of hematogenous spread, referred to as peritoneal carcinomatosis without distant disease. Cytoreductive surgery combined with hyperthermic intraperitoneal chemotherapy with mitomycin C and post-operative systemic chemotherapy, has resulted in a median survival of up to 42 months in these patients when a complete cytoreduction is achieved. On 14–16 January 2006 the first International Symposium on Regional Cancer Therapies was held in Snowmass, Colorado. Surgical options in the management of peritoneal surface malignancies of colonic origin (Table 1), were re-

TABLE 1. Literature review of most recent updates on cytoreductive surgery and hyperthermic intraperitoneal chemotherapy (HIPEC) in the management of peritoneal surface malignancies of colonic origin

Chief investigator	Center	Design	Year	Patient (n)	HIPEC	Follow-up (months)	Median survival (months)	Survival (%)				
								One year	Two years	Three years	Four years	Five years
Verwaal ¹	Amsterdam	Phase III	2004	54	MMC arm	22	22	67	44	–	–	–
				51	Control arm			56	22	–	–	–
Rossi ²	Padova	Phase II	2003	46	MMC + Cisplatin	15	18	68	31	–	–	–
Di Filippo ³	SITIL0	Phase II	2003	69	MMC	–	–	–	–	27	–	–
Levine ⁴	Winston-Salem	Phase II	2004	77	MMC	15	16	56	–	25	–	17
Gilly ⁵	Lyon	Phase II	2004	53	MMC	60	13	55	–	32	–	11
Glehen ⁶	Multi-centers	Phase II	2004	506	MMC/LOHP	53	19	72	–	39	–	19
Morris ⁷	Sydney	Phase II	2005	30	MMC	12	30	71	62	–	–	–
Kecmanovic ⁸	Belgrade	Phase II	2005	18	MMC	21	15	–	–	–	–	–
Elias ⁹	Villejuif	Phase II	2005	30	LOHP	55	60	97	73	53	49	–
Zoetmulder ¹⁰	Amsterdam	Phase II	2005	117	MMC	46	22	75	–	28	–	19
Sugarbaker ¹¹	Washington	Phase II	2005	70	MMC	47	33	88	–	44	–	32

MMC mitomycin C; LOHP oxaliplatin; 5-FU 5-fluorouracil

viewed and discussed by some representatives from the major Peritoneal Surface Malignancy Centers from around the world. During a follow up meeting on 24 March 2006 in San Diego, CA, while attending the Society of Surgical Oncology annual meeting, further discussions concluded in agreement on a registry database sheet and using the Peritoneal Cancer Index as a scoring system (Table 2). Based on the analysis of published data, we present a Consensus Statement on the treatment of patients with recurrent and/or metastatic colon cancer with peritoneal involvement (Fig. 1).

Rigorous Diagnostic Work-up

Proper patient selection has been shown to be a crucially important aspect of this treatment plan. Once a patient has been diagnosed with colon cancer with peritoneal involvement, the work-up should include a complete colonoscopic evaluation as well as a CT scan of the chest, abdomen and pelvis with maximum oral and IV contrast to evaluate the extent of peritoneal dissemination. A PET scan can be considered if there is any question of extra-abdominal disease.

Best Systemic Therapy

Patients that are diagnosed as having peritoneal carcinomatosis and other sites of dissemination and that have a good performance status, should receive the best combination of cytotoxic chemotherapy and biological agents. If they have a good response to the

systemic therapy and/or if they have limited liver involvement, they may be considered for cytoreductive surgery and intraperitoneal chemotherapy at a later time. There is currently little data to guide us as to whether such chemotherapy is best given before or after cytoreductive surgery and HIPEC. However, we feel that patients should be evaluated by surgical oncologists experienced in these techniques prior to embarking on systemic therapy alone for patients who may be candidates for HIPEC.

Variables Associated with Increased Chances of having a Complete Cytoreduction

Complete cytoreduction means that no macroscopic residual disease was left after the operative procedure. The following are clinical and radiographic variables that are usually associated with increase chances of achieving a complete removal of all tumor greater than 2.5 mm:

- (1) ECOG performance status two or less;
- (2) no evidence of extra-abdominal disease;
- (3) up to three small, resectable parenchymal hepatic metastases;
- (4) no evidence of biliary obstruction;
- (5) no evidence of ureteral obstruction;
- (6) no evidence of intestinal obstruction at more than one site;
- (7) small bowel involvement: no evidence of gross disease in the mesentery with several segmental sites of partial obstruction;
- (8) small volume disease in the gastro-hepatic ligament.

TABLE 2. Clinical pathway for the management of peritoneal surface malignancies of colonic origin database sheet

Institution _____ Patient Number _____ DOB _____ Sex M ___ F ___ Surgeon _____
 Date of Cytoreductive Surgery _____ OR Time _____ EBL _____ PRBC's _____ Ascites Drained _____
 HIPEC Yes ___ No ___ Open ___ Closed ___ Drug _____ Dose _____ Inflow Temp _____
EPIC Yes ___ No ___ Drug _____ Dose _____ Number of Days _____

Cytoreduction Details

Anastomoses

SB-SB _____
 Gastro-SB _____
 SB-Colon _____
 Colon-Colon _____
 Colon-Rectum _____
 SB-Rectum _____

EXTENT OF RESECTIONS

Colon _____ SB _____
 Low Anterior _____
 Spleen _____ Panc _____
 Gallbladder _____ Bladder _____
 G Oment _____ L Oment _____
 Liver mets _____ Stomach _____
 Uterus _____ Ovaries _____
 Other _____

PERITONECTOMIES

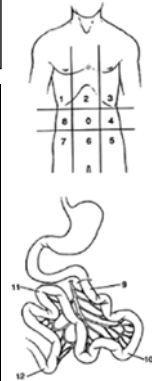
Parietal _____
 Pelvic _____
 Omental Bursa _____
 RUQ _____ LUQ _____

PCI SCORE			
CT/Laparosc	Regions	Lesion at Exploration	Lesion Post Surgery
	0 Central		
	1 Right Upper		
	2 Epigastrium		
	3 Left Upper		
	4 Left Flank		
	5 Left Lower		
	6 Pelvis		
	7 Right Lower		
	8 Right Flank		
	9 Upper Jejunum		
	10 Lower Jejunum		
	11 Upper Ileum		
	12 Lower Ileum		
	SCORE		

LESION SIZE SCORE

LS 0	No Tumor Seen
LS 1	Tumor up to 0.5 cm
LS 2	Tumor up to 5.0 cm
LS 3	Tumor > 5.0 cm or confluence

	CT	At Exploration	Post Surgery
Zone II Involved Y or N			
Small Bowel Class			



Colostomy: Y ___ N ___ Permanent: Y ___ N ___
 Ileostomy: Y ___ N ___ Permanent: Y ___ N ___

CC SCORING	RR SCORING
No Disease :CC 0: _____	R0: _____ Complete removal of all visible tumor, negative cytology or negative microscopic margins
<= 0.25 cm : CC 1: _____	R1: _____ Complete removal of all visible tumor, positive cytology or microscopic margins
0.25-2.5 cm :CC 2: _____	R2a: _____ Minimal residual tumor, nodule (s) <= 0.5 cm
>=2.5 cm :CC 3: _____	R2b: _____ Gross residual tumor, nodule (s) > 0.5 cm, but <= 2 cm
	R2c: _____ Extensive disease remaining, nodule (s) > 2 cm

Institution _____ Patient Number _____ Surgeon _____
 Date of Cytoreductive Surgery _____ ICU Length of Stay (LOS) _____ Total Hospital LOS _____

Primary Tumor Stage

Site: **R T L S**
T ___ **N** ___ **M** ___
 Mucinous: Y ___ N ___
 Well Diff _____
 Mod Diff _____
 Poorly Diff _____
 Signet Ring _____
 Liver mets _____

Previous Surgeries None ___

Date _____
 Procedure 1 _____
 Date _____
 Procedure 2 _____
 Date _____
 Procedure 3 _____

Previous Chemotherapy None ___

Date _____
 Regimen 1 _____
 Date _____
 Regimen 2 _____
 Date _____
 Regimen 3 _____
Previous XRT: Y ___ N ___

Cytoreduction Path

Mucinous: Y ___ N ___
 Well Diff: _____
 Mod Diff: _____
 Poorly Diff: _____
 Signet Ring: _____
 Lymph nodes _____
 Liver mets: Number _____ Resected _____

Cytoreduction Morbidity

Pancreatitis Y ___ N ___
 Fistula Y ___ N ___
 Leak Y ___ N ___
 PE Y ___ N ___
 DVT Y ___ N ___
 Re-Op Y ___ N ___
 Cause _____
 Hematologic Y ___ N ___

 Death Y ___ N ___
 Death Cause _____
 Re-admission Y ___ N ___
 Cause _____
 Other _____

Follow-up Status

Date _____
 Status _____
 Recurrence Site _____
 Date _____
 Status _____
 Recurrence Site _____

Cytology: Positive ___ Neg ___ N/A ___

Others

Pre Op CEA _____ Date _____
 Post Op CEA _____ Date _____

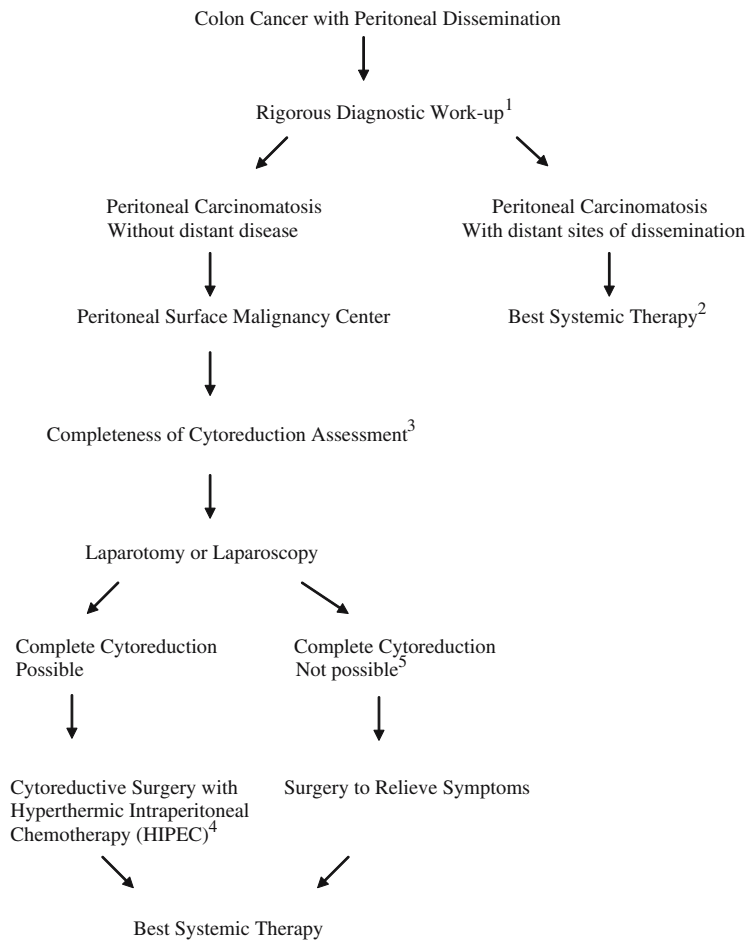


FIG. 1. Clinical pathway for the management of peritoneal surface malignancies of colonic origin.

Cytoreductive Surgery and Hyperthermic Intraperitoneal Chemotherapy

Cytoreductive surgery will include peritonectomy procedures in order to remove all visible tumor. If a complete cytoreduction, CC-0/CC-1 by the completion of cytoreduction score or a R0/R1 by the R scoring system is achieved (see Table 2), then the patients will undergo hyperthermic intraperitoneal chemotherapy (HIPEC) with mitomycin C (15–35 mg/m²) with a target intraperitoneal temperature of 39–42°C for 60–120 min. Whether an open or closed method for the chemotherapeutic perfusion is used, and whether or not early post-operative intraperitoneal chemotherapy (EPIC) with 5-FU is used, will be the surgeon's preference. In those patients with symptomatic ascites in whom an adequate cytoreduction could not be achieved, HIPEC could be performed at the discretion of the surgeon with the intention of palliating the intractable ascites. Although mitomycin C is the most commonly used drug, we recognized that oxaliplatin

is being used more frequently with very promising results.

Complete Cytoreduction Not Possible

In those patients with clear evidence of incomplete cytoreduction, surgery should be performed to relieve symptoms at the discretion of the operating surgeon.

REFERENCES

1. Verwaal VJ, van Ruth S, de Bree E, et al. Randomized trial of cytoreduction and hyperthermic intraperitoneal chemotherapy versus systemic chemotherapy and palliative surgery in patients with peritoneal carcinomatosis of colorectal cancer. *J Clin Oncol* 2003; 21(20):3737–43.
2. Pilati P, Mocellin S, Rossi CR, et al. Cytoreductive surgery combined with hyperthermic intraperitoneal intraoperative chemotherapy for peritoneal carcinomatosis arising from colon adenocarcinoma. *Ann Surg Oncol* 2003; 10(5):508–13.
3. Cavaliere F, Perri P, Rossi CR, et al. Indications for integrated surgical treatment of peritoneal carcinomatosis of colorectal

- origin: experience of the Italian Society of Locoregional Integrated Therapy in Oncology. *Tumori* 2003; 89(Suppl 4):21–3.
4. Shen P, Hawksworth J, Lovato J, et al. Cytoreductive surgery and intraperitoneal hyperthermic chemotherapy with mitomycin C for peritoneal carcinomatosis from nonappendiceal colorectal carcinoma. *Ann Surg Oncol* 2004; 11(2):178–86.
 5. Glehen O, Cotte E, Schreiber V, Sayag-Beaujard AC, Vignal J, Gilly FN. Intraperitoneal chemohyperthermia and attempted cytoreductive surgery in patients with peritoneal carcinomatosis of colorectal origin. *Br J Surg* 2004; 91:747–54.
 6. Glehen O, Kwiakowski F, Sugarbaker PH, et al. Cytoreductive surgery combined with perioperative intraperitoneal chemotherapy for the management of peritoneal carcinomatosis from colorectal cancer: a multi-institutional study. *J Clin Oncol* 2004; 22(16):3284–92.
 7. Kecmanovic DM, Pavlov MJ, Ceranic MS, Sepetkovski AV, Kovacevic PA, Stamenkovic AB. Treatment of peritoneal carcinomatosis from colorectal cancer by cytoreductive surgery and hyperthermic perioperative intraperitoneal chemotherapy. *Eur J Surg Oncol* 2005; 31:147–52.
 8. Yan TD, Links M, Kam P, Morris DL. Cytoreductive surgery combined with perioperative intraperitoneal chemotherapy for colorectal peritoneal carcinomatosis. Submitted for publication.
 9. Elias D, Raynard B, Farkhondeh F, et al. Peritoneal carcinomatosis of colorectal origin: long-term results of intraperitoneal chemohyperthermia with oxaliplatin following complete cytoreductive surgery. Submitted for publication.
 10. Verwaal VJ, van Ruth S, Witkamp A, Boot H, van Slooten G, Zoetmulder FAN. Long-term survival of peritoneal carcinomatosis of colorectal origin. *Ann Surg Oncol* 2005; 12(1):65–71.
 11. da Silva RG, Sugarbaker PH. Analysis of 10 prognostic factors in 70 patients having a complete cytoreduction plus perioperative intraperitoneal chemotherapy for carcinomatosis from colorectal cancer. Submitted for publication.